

# Permanent Pacemaker Implantation with Near-zero Fluoroscopy in 17-year-old Pregnant Woman with Multiple Aborted Cardiac Arrests caused by Pause-Dependent Torsades de Pointes due to Total Atrioventricular Block and a Prolonged QT Interval

Muzakkir Amir<sup>a</sup>, Hafiz Idul Fitranul<sup>a\*</sup>, Levina<sup>a</sup>

<sup>a</sup>Department of Cardiology and Vascular Medicine, Hasanuddin University, Makassar 90245, Indonesia

\*Jalan Perintis Kemerdekaan Km 10, Makassar, South Sulawesi

Corresponding email : [muzakkir@unhas.ac.id](mailto:muzakkir@unhas.ac.id)

ORCID ID : 0000-0002-4914-3542

## Abstract:

A 17-year-old female, pregnant for 18 weeks, presented with Torsades de Pointes due to total AV block and prolonged QT interval. We implanted a pacemaker with cumulative dose-area-product of 54.7mGy/cm<sup>2</sup> (estimated uterus dose 6.5mGy/cm<sup>2</sup>), and cumulative air kerma of 0.15mGy. Upon follow-up, the patient gave birth to a normal baby on 34th week of pregnancy.

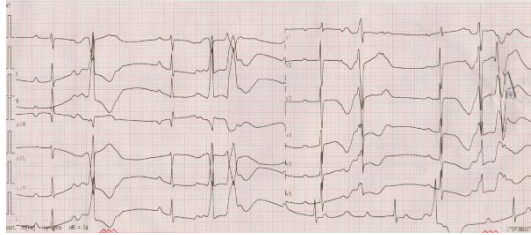
**KEYWORDS:** *Cardiac arrest, permanent pacemaker, pregnancy, prolonged QT interval, torsades de pointes, total AV block.*

## Introduction

Various arrhythmias could occur during or triggered by pregnancy. While ectopic beats/non-sustained arrhythmias were experienced by more than half of pregnant women, the prevalence of sustained arrhythmias are at 2-3/1000.<sup>1</sup> Total AV block could occur during or just diagnosed during pregnancy.<sup>2</sup> Isolated complete heart blocks during pregnancy have generally favorable outcomes when the escape rhythms have narrow QRS complexes.<sup>3</sup> Implantation of permanent pacemaker during pregnancy poses the fetus to the risks of ionizing radiation.<sup>4</sup>

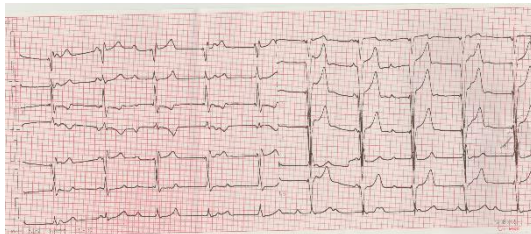
## Case Presentation

A 17-year-old female, pregnant for 18 weeks, referred to our ER with multiple cardiac arrest episodes. An ECG upon arrival showed a total atrioventricular block with a prolonged QT interval and ventricular escape rhythm with R-on-T configuration (Figure 1).



**Figure 1.** Patient's ECG after ROSC

The R-on-T phenomenon was immediately followed by an episode of cardiac arrest with Torsades de Pointes (TdP) that was captured on the ECG monitor. The patient was defibrillated four times with concomitant administration of magnesium sulphate. The laboratory results showed hypokalemia of 2.7 meq/L. We performed a potassium correction using potassium chloride, and the patient no longer experienced any TdP episodes. However, the total atrioventricular block persisted (Figure 2). A bedside echocardiography showed no structural abnormality.



**Figure 2.** The ECG after potassium correction

After a consultation with the obstetrics department, a fetal ultrasound showed a living 18-week fetus with a fetal heart rate of 149.2 bpm. The obstetrician found nothing significant in her history except for hyperemesis gravidarum.

### **Treatment and Intervention**

Even though the fetal ultrasound showed no signs of fetal distress, imminent hemodynamic deterioration was still a concern. Therefore, we decided to implant a single chamber pacemaker with minimal fluoroscopy and proper abdominal shielding to avoid adverse radiation effects on the fetus. Following mild sedation, an infraclavicular pocket was created. Left subclavian vein access was obtained, and a guidewire was inserted. The catheter was then proceeded to the right atrium and right ventricle, and an active ventricular lead (Medtronic CAPSUREFIX NOVUS MRITM SURESCANTM) was screwed to the apex. The lead was interrogated and showed a pacing threshold at 1.0 V, R-wave sensing at 7.7 mV, and an impedance of 667 ohms. Three courses of fluoroscopy were used at the time of puncture, during lead insertion, and at the end of the procedure to determine the lead position. Cumulative fluoroscopy time was 13 seconds with a cumulative DAP from fluoroscopy of 54.7 mGy/cm<sup>2</sup> (estimated uterus dose 6.5 mGy/cm<sup>2</sup>), a cumulative air kerma from exposure of 0 (total DAP of 54.7 mGy/cm<sup>2</sup>) and a cumulative air kerma of 0.15 mGy. Leads were anchored and connected to a pulse generator (Medtronic SENSIATM SES01). The pacemaker was set on VVI mode at 60 bpm. A definitive cause of total atrioventricular block in this patient could not be determined. The patient was monitored for three days in hospital with good tolerance for the pacemaker. To anticipate hemodynamic changes during pregnancy, the pacemaker was then set to 70 bpm. The patient was then discharged home.

### **Follow-up and Outcome**

The pregnancy was followed by an obstetrician and monthly examinations showed proper fetal growth and no identified abnormalities. Unfortunately, on her 34th week of pregnancy, the patient experienced abdominal trauma when she was riding in a car and premature rupture of membrane ensued. The patient gave birth to a 2200-gram male baby by assisted vaginal labor. There were no congenital abnormalities observed during routine newborn examination. No arrhythmic event was noted during labor and puerperal period.

## Discussion

Total atrioventricular block can be caused by congenital, acquired, or degenerative causes<sup>2</sup> with approximately 1:5000 to 1:20000<sup>8</sup>. Isolated complete heart blocks during pregnancy have generally favorable outcomes when the escape rhythms have narrow QRS complexes. Unfortunately, in our patient, the total AV block came in combination with a prolonged QT interval and an escape rhythm with a wide QRS causing R-on-T phenomenon and consequent TdP.<sup>3</sup>

The prolonged QT interval in this patient was possibly induced by hypokalemia. Hypokalemia lengthens the repolarization of cardiac myocytes, therefore increasing T wave duration and prolonging the QT interval. Hypokalemia can potentially cause QT interval prolongation with subsequent risk of TdP.<sup>9</sup> In this patient, hypokalemia was thought to be caused by hyperemesis gravidarum and reduced oral intake.<sup>10,11</sup>

Repeated episodes of TdP requiring multiple defibrillations raised our concern about maternal and fetal hemodynamic instability. Temporizing measures, such as the administration of intravenous magnesium and potassium, managed to cease multiple TdP episodes. Nevertheless, with a persistent total atrioventricular block, the risk of pause dependent TdP remained. The patient met a class I indication for permanent pacemaker implantation.<sup>12</sup> Yet, the risk of fetal irradiation is a major concern. Some cases have managed to overcome this concern using non-fluoroscopic electroanatomic mapping<sup>6,7</sup> or transesophageal echocardiography<sup>5</sup>, but these measures were not available in our center. The 2018 ESC Guideline on Management of Cardiovascular Disease during Pregnancy stated that the implantation of a single chamber implantable cardioverter-defibrillator or permanent pacemaker can be performed safely, especially when the fetus is beyond 8 weeks of gestation.<sup>13</sup> Weighing the benefits against the risks, we decided to perform a single chamber permanent pacemaker implantation using minimal fluoroscopy.

We were able to implant the permanent pacemaker with a total DAP of 54.7 mGy. We managed to reduce radiation dose by minimizing the angulation of the X-ray source and taking a minimal amount of acquisition runs. The American College of Obstetricians and Gynecologists Committee Opinion on Guidelines for Diagnostic Imaging during Pregnancy and Lactation suggested a threshold of 250-280 mGy on 16-25 weeks pregnancy.<sup>4</sup> In our case, we estimate that the fetal dose was 0.15 times the entrance skin dose, which is 8.0 mGy.<sup>14</sup> We set the permanent pacemaker with a default heart rate of 60 bpm, and the patient experienced no further symptoms.

The implantation of permanent pacemaker managed to save the patient's life and subsequent pregnancy was uneventful. Known ionizing radiation effect during pregnancy were abortion, growth restriction, intrauterine fetal death, premature birth, microcephaly, and various congenital anomalies.<sup>4</sup> Despite the baby's premature born incited by abdominal trauma.

## References

1. Adamson DL, Nelson Piercy C. 2007. Managing Palpitations and Arrhythmia during pregnancy. *Heart* 93:1630-1636.
2. Baghel K, Mohsin Z, Ozair M. 2016. Pregnancy with Complete Heart Block, *J. Obstet Gynaecol India* 66(Suppl2):623-625.
3. Friedman D., Duncanson L., Glickstein J., and Buyon P. 2003. A review of congenital heart block. *Images in Paediatric Cardiology* 5(3):46-48.
4. Committee on Obstetric Practice. 2018. Guidelines on for Diagnostic Imaging during Pregnancy and Lactation. *ACOG Committee Opinion* 131(728):e210-215.
5. Jordaens L., Vandenbogaerde J., Van De Bruaene, M. 1990. Transesophageal Echocardiography for Insertion of a Physiological Pacemaker in Early Pregnancy. *PACE* 13:955-957.
6. Chua K.C.M., Lim E. T. S., Chong D. T. T., Tan B. Y., Ho K. L., and Ching C. K. 2017.

- Implantation of a dual-chamber permanent pacemaker in a pregnant patient guided by intracardiac echocardiography and electroanatomic mapping. *Heart Case Reports* 3(11):542-545.
7. Elbadawi A., Arif Z., Chuprun D., and Rao M. 2016. Permanent pacemaker implantation without fluoroscopy in a pregnant woman with complete atrioventricular block: A case report. *Indian Pacing Electrophysiology Journal*, vol. 16, no. 5, pp. 172-174.
  8. Perloff J.K and Marelli A.K. *Perloff's Clinical Recognition of Congenital Heart Disease*. 6th ed. Philadelphia: Elsevier; 2012.
  9. Widimsky P. 2008. Hypokalemia and the heart. *E-Journal ESC Council on Cardiology Practices* 7(9).
  10. Kardalas E., Paschou S. A., Anagnostis P., Muscogiuri G., Siasos G., and Vryonidou A. 2018. Hypokalemia: a clinical update. *Endocrinology Connections*, 7(4):135-146.
  11. London V., Grube S., Sherer D. M., and Abulafia O. 2017. Hyperemesis gravidarum: A review of recent literature. *Pharmacology* 100(3-4):161-171.
  12. Brignole M., Auricchio A., G. Baron-Esquivias, et al. 2013. 2013 ESC Guidelines on cardiac pacing and cardiac resynchronization therapy. *European Heart Journal* 34 (29): 2281-2329.
  13. Regitz-Zagrosek V., Roos-Hesselink J.W., Bauersachs J., Blomstrom Lundqvist C., et al., 2018. 2018 ESC guidelines for the management of cardiovascular diseases during pregnancy. *European Heart Journal*: 39(34):3165-3241.
  14. M. Mahesh. 2011. Dosimetry in pregnant patients undergoing CT and fluoroscopy. Paper presented at The 2011 Joint AAPM/COMP Meeting, 31 July-4 August, Vancouver, Canada.

#### **Figure Legends**

- Figure 1. Patient's ECG after ROSC showing a total atrioventricular block, HR 54 bpm with prolonged QT interval, and ventricular escape rhythm with R-on-T configuration.
- Figure 2. The ECG after potassium correction showing a total atrioventricular